



**The University of Alabama at Birmingham School of Medicine  
Department of Dermatology**

Presents

**The 37th Annual  
Southeastern Consortium for CME in Dermatology**  
*Patient Presentations and  
Clinical Session*

Sunday, November 3, 2013  
The Kirklin Clinic, UAB Campus  
2000 6<sup>th</sup> Avenue South  
Birmingham, AL 35233



**UAB MEDICINE**  
DERMATOLOGY

Sunday, November 3, 2013

*Patient Presentations*

The Kirklín Clinic  
UAB Campus  
2000 6<sup>th</sup> Avenue South  
Birmingham, AL 35233

- 7:30 am Shuttle departs The Hyatt Regency-Wynfrey Hotel
- 8:00 Registration/Continental Breakfast – Kirklín Clinic 3<sup>rd</sup> floor
- 8:30 Patient Viewing – Kirklín Clinic 3<sup>rd</sup> & 4<sup>th</sup> floors

*Clinical Session*

Margaret Cameron Spain Auditorium  
Spain Wallace Building, 1<sup>st</sup> floor  
Corner of 7th Ave. S & 19th St. S  
(see map on next page for details)

Moderators: S. Lauren Hughey, MD  
Amy Theos, MD  
Kathleen Beckum, MD  
Kristopher McKay, MD

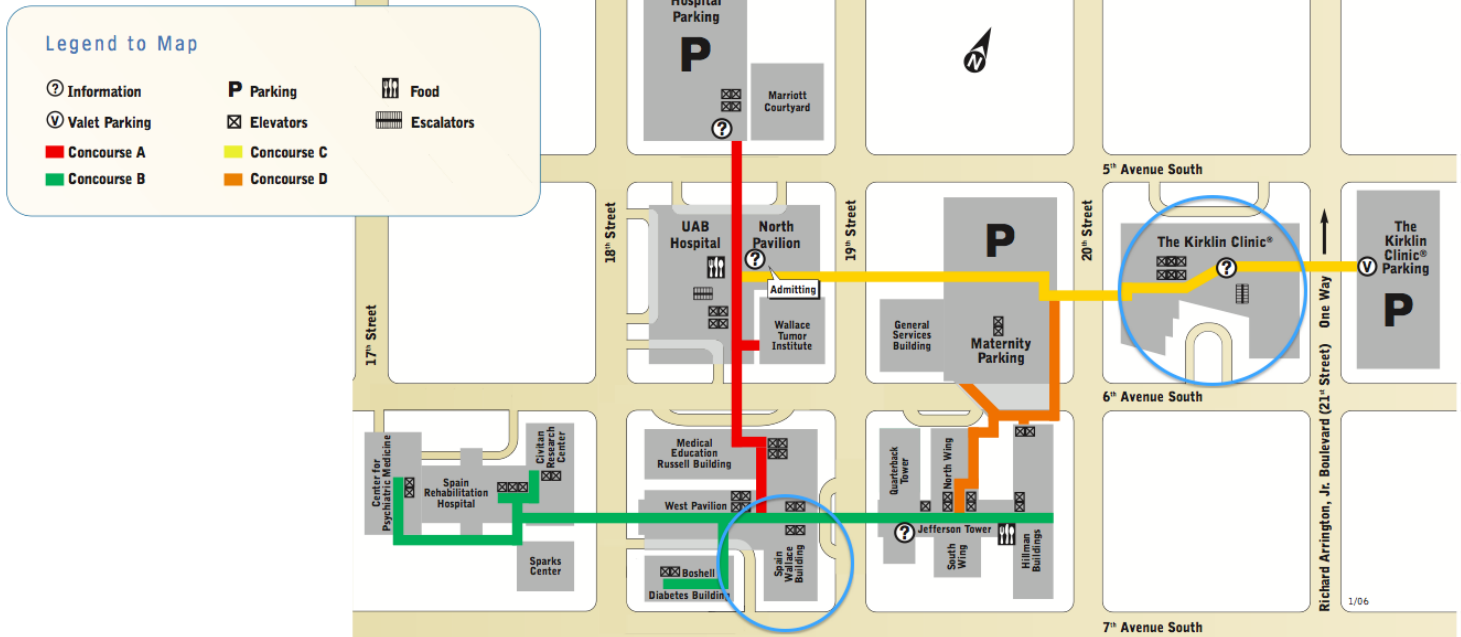
Guest Faculty: Jean Bolognia, MD  
Dirk Elston, MD

- 10:15 Case Discussions
- 12:00 pm Adjournment
- 12-12:30 Shuttle departs for airport

## Directions to Margaret Cameron Spain Auditorium

### UAB Hospital - Level 2 Concourse System

The facilities shown here are accessible to one another by a system of interior walkways and covered crosswalks, which are located on the second floor of each building.



- There is a covered walkway from Kirklin Clinic to the Margaret Cameron Spain Auditorium on the 2<sup>nd</sup> floor
- From Kirklin Clinic, follow signs towards “North Pavilion” (Concourse C)
- Once you reach North Pavilion (look for Starbucks), follow signs towards “Spain Wallace” (turn left onto Concourse A)
- The Margaret Cameron Spain Auditorium is on the first floor of the Spain Wallace Building

# Table of Contents

## **Epidermal Tumors**

Porokeratotic Eccrine Ostial and Dermal Duct Nevus	1
Inflammatory Linear Verrucous Epidermal Nevus	2
Epidermal Nevus	3
Clear Cell Papulosis	4
Disseminated Superficial Porokeratosis	5
Eruptive Syringomas	6

## **Connective Tissue, Dermal Fibrosis and Elastic Tissue Disorders**

Elastosis Perforans Serpiginosa	7
Pseudoxanthoma Elasticum	8
Anetoderma	9
Granulomatous Scleromyxedema	10
Atrophoderma	11
Nephrogenic Systemic Fibrosis	12
Stiff Skin Syndrome	13
Lipodystrophy	14

## **Genodermatoses**

Neurofibromatosis Type 1 and Gorlin Syndrome	15
Gorlin Syndrome	16
Tuberous Sclerosis Complex	17
Cowden Syndrome	18
Lamellar Ichthyosis	19
Bathing Suit Ichthyosis	20
Aquagenic Wrinkling of the Palms	21
CHILD Syndrome	22
Darier Disease	23
Hailey-Hailey Disease	24
Nail-Patella Syndrome	25
Brooke-Spiegler Syndrome	26
Incontinentia Pigmenti	27
Goldenhar Oculo-Auriculo-Vertebral Syndrome	28
Ankyloblepharon-Ectodermal Dysplasia-Clefting Syndrome	29
Legius Syndrome	30

## **Other Neoplastic Disorders**

Systemic Mastocytosis	31
Urticaria Pigmentosa	32
Concomitant Cutaneous T-Cell Lymphoma and Vitiligo	33

# Table of Contents, Continued

## **Vascular Malformations and Neoplasms**

Familial Glomuvenous Malformation	34
Multifocal Lymphangioendotheliomatosis with Thrombocytopenia	35
Kaposiform Hemangioendothelioma	36
Phakomatosis Pigmentokeratolica	37
Sturge-Weber Syndrome	38
Benign Lymphangioendothelioma	39

## **Diseases of Skin Appendages**

Uncombable Hair Syndrome	40
Monilethrix	41
Yellow Nail Syndrome	42
Frontal Fibrosing Alopecia (two cases)	43
Alopecia Universalis	44
TNF- $\alpha$ Inhibitor Associated Alopecia Areata	45

## **Granulomatous Processes**

Rosai-Dorfman Disease	46
Necrobiotic Xanthogranuloma	47
Multiple Adult Xanthogranuloma	48
Granulomatous Disorder NOS	49

## **Pigmentation Disorders**

Piebaldism	50
Oculocutaneous Albinism	51
Imipramine-Induced Hyperpigmentation	52
Halo Nevi	53

## **Bullous Diseases**

Pemphigus Foliaceus	54
Linear IgA Bullous Dermatitis	55
Epidermolysis Bullosa Nevus	56

## **Other**

Fabry Disease	57
SAPHO Syndrome	58
Erythroderma	59